PVC originating from RCC of aortic valve

Saruul Tseveendee

Shastin Third State Hospital

Clinical case

Patient 28 y.o/M

Brief Hx	
Complain	Dizziness, lightheadedness
Holter recordings	PVC 42.7% (2015-02-24), 38.6% (2016-11-16), 41.77% (2017-02-15)
Echo findings	No structural heart disease, EF 57%
Medication	Beta-blocker for 2 years

ECG #2 (2017-02)

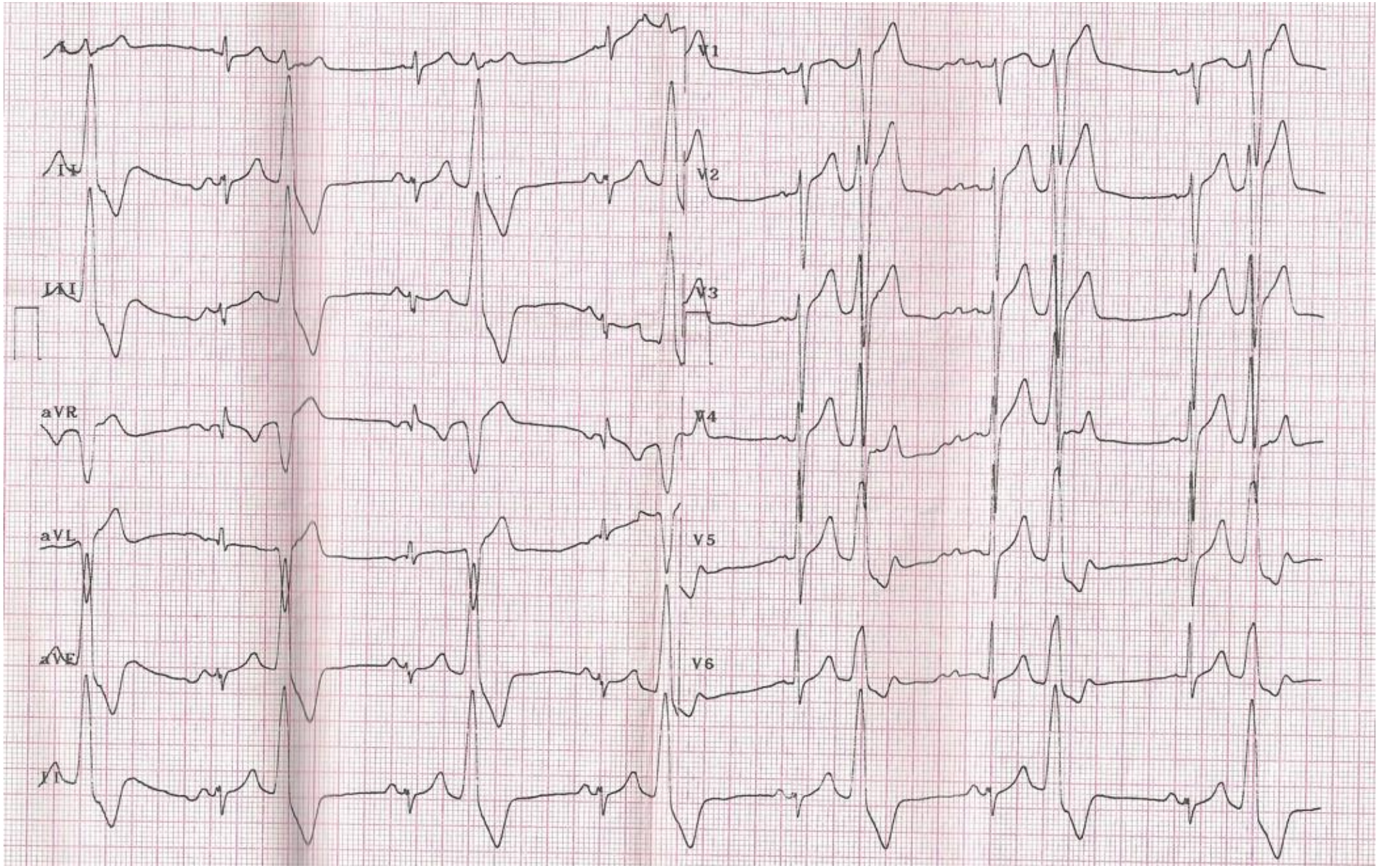

ECG #1 (2015-02)

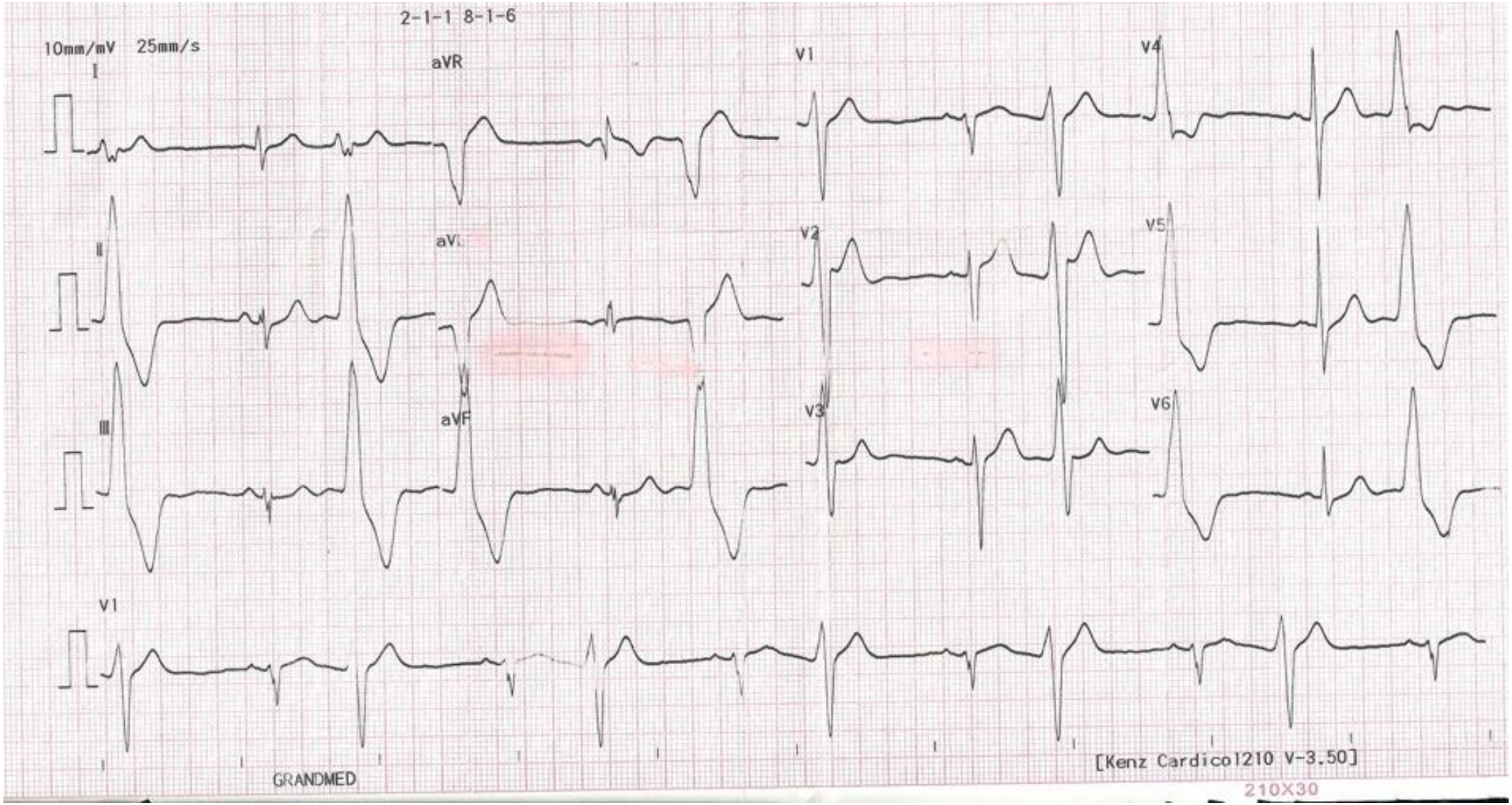
2-1-1 8-1-6
10mm/mV 25mm/s
I
aVR
V1
V4
II
aVL
V2
V5
III
aVF
V3
V6
V1
GRANDMED
[Kenz Cardico1210 V-3.50]
210X30

Localizing PVC origin

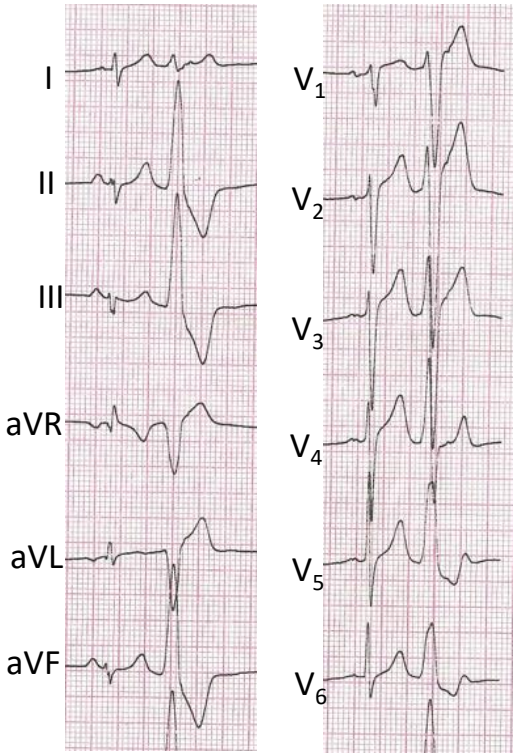

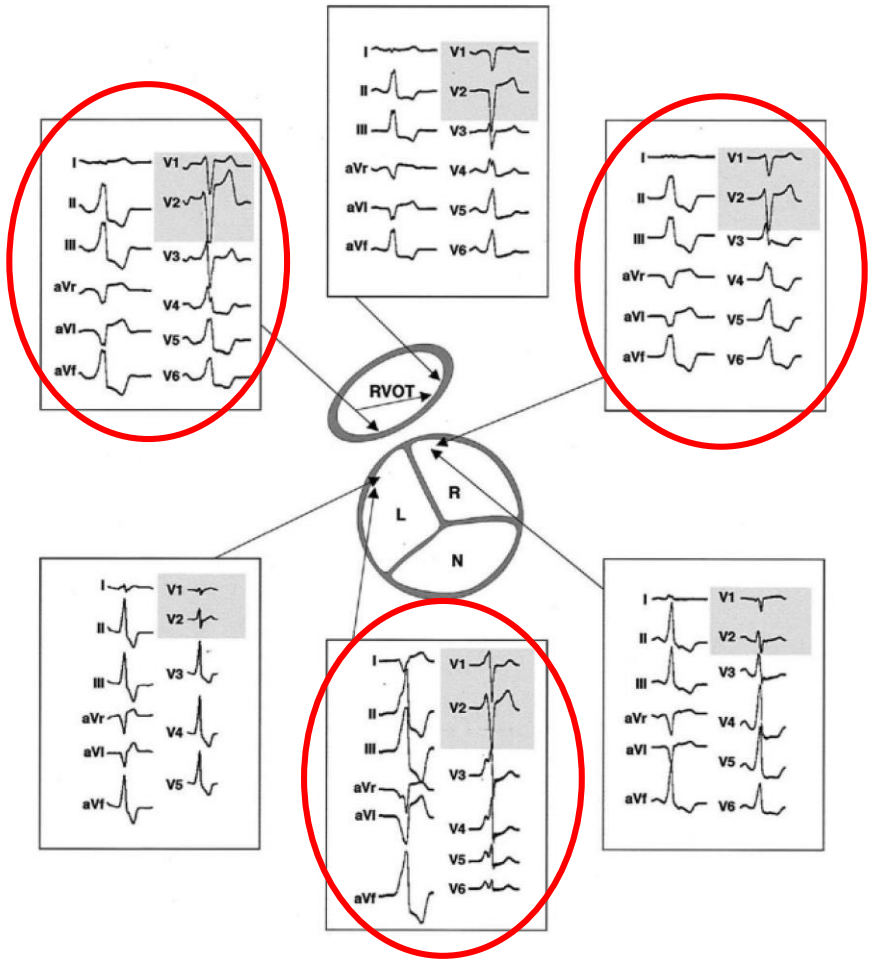

Ouyang F. J Am Coll Cardiol 2002;39:500

Localizing PVC origin

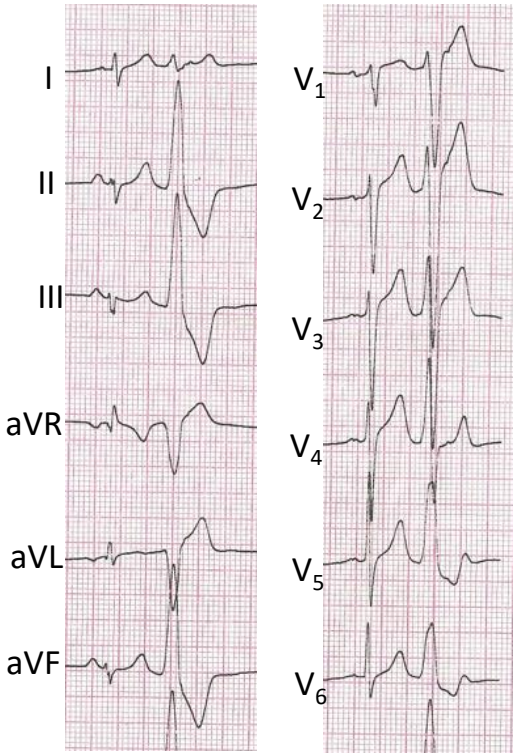

Localization of Optimal Ablation Site of Idiopathic Ventricular Tachycardia from Right and Left Ventricular Outflow Tract by Body Surface ECG

Shiro Kamakura, MD; Wataru Shimizu, MD; Kiyotaka Matsuo, MD; Atsushi Taguchi, MD; Kazuhiro Suyama, MD; Takashi Kurita, MD; Naohiko Aihara, MD; Tohru Ohe, MD; Katsuro Shimomura, MD

1. QRS polarity of lead I- rS pattern
2. Initial r-wave amplitude in leads V1 and V2 was high
3. The QS wave amplitude in leads aVR and aVL was useful. If the QS wave depth in lead aVL was larger than that in lead aVR,
4. Lead AVL shows initial 40 ms of PVC is isoelectric

Kamakura et al., Circulation 1998; 98: 1525-1533

Ablation catheter on LCC

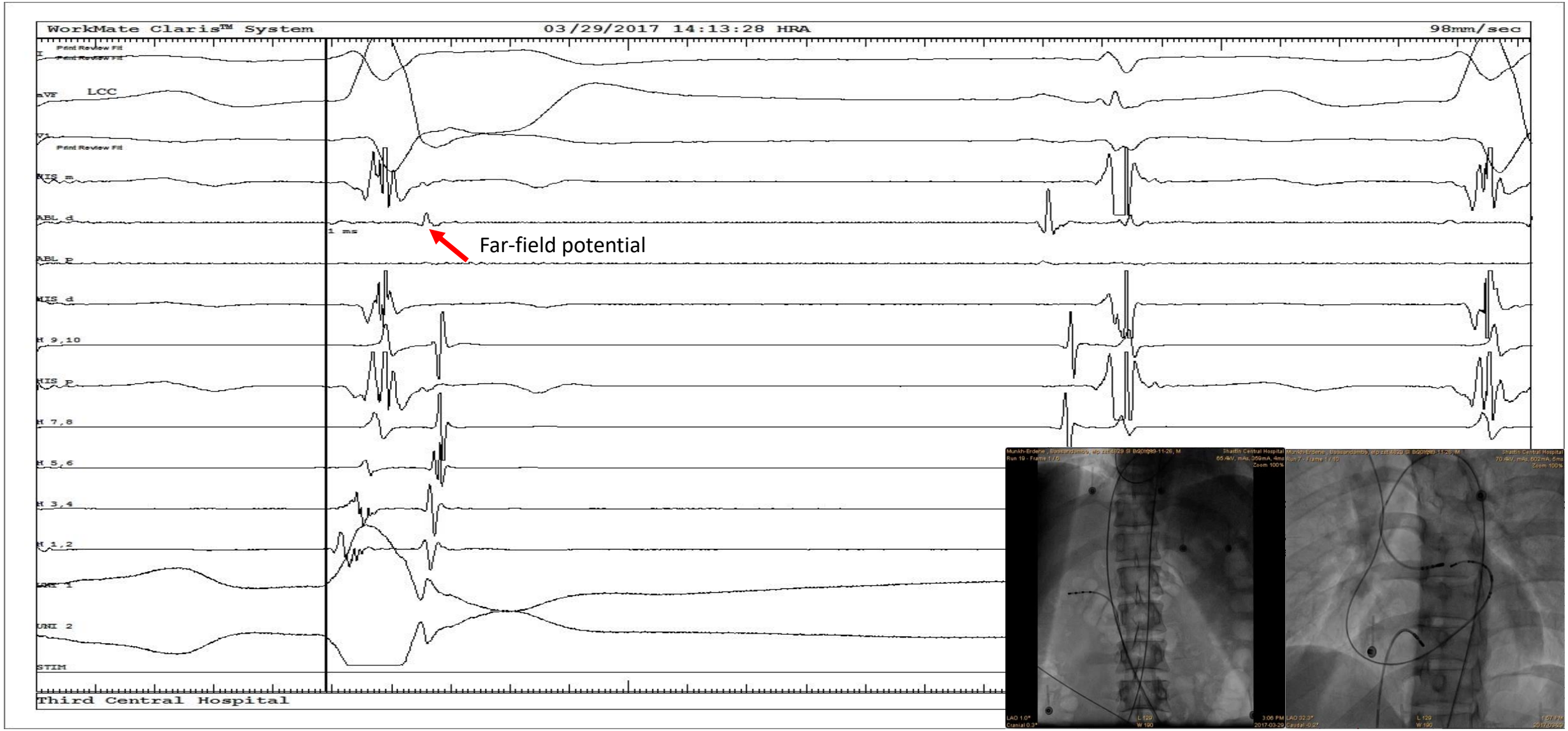

Ablation catheter on RCC

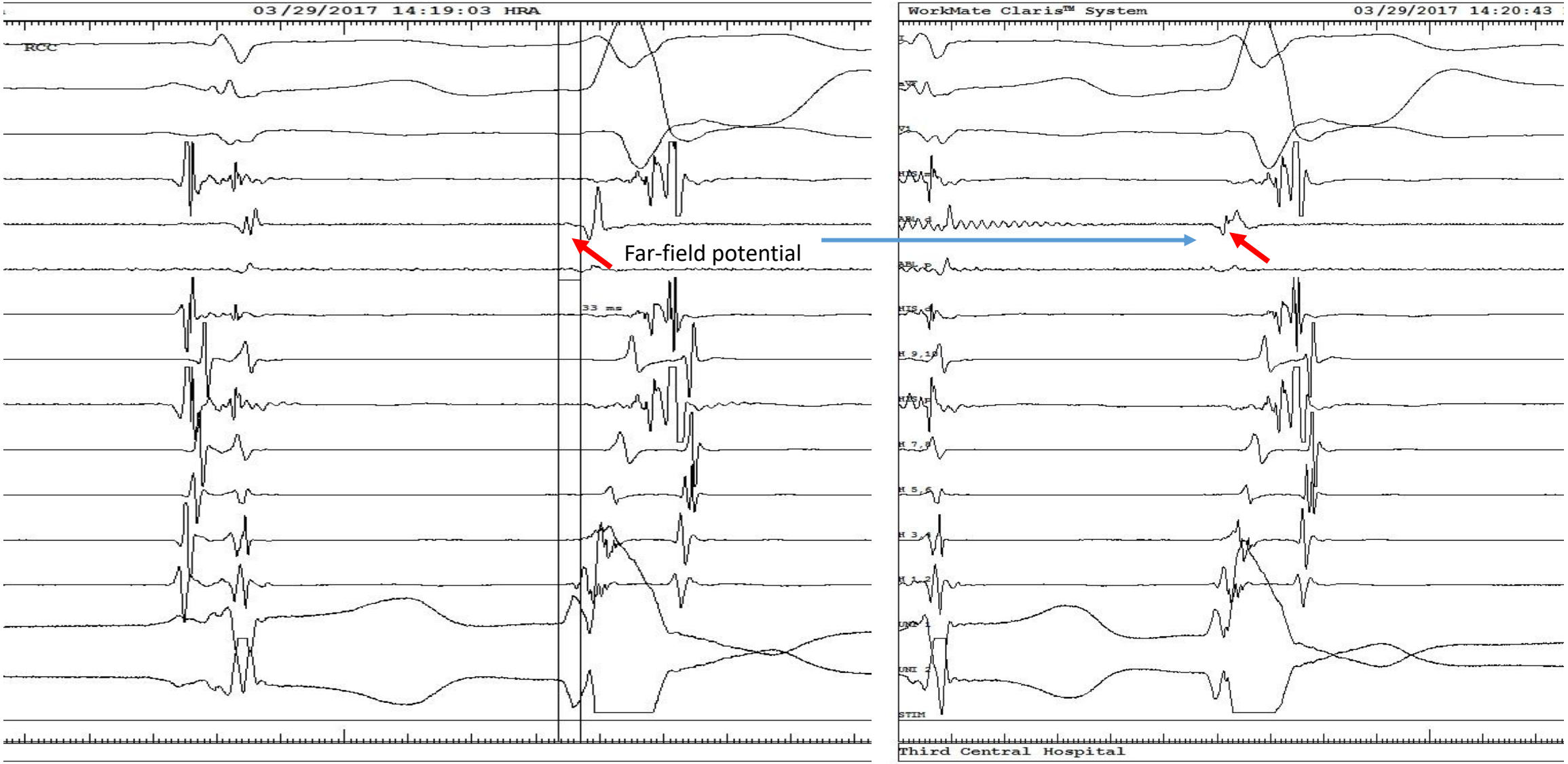

Ablation catheter under the Aortic valve

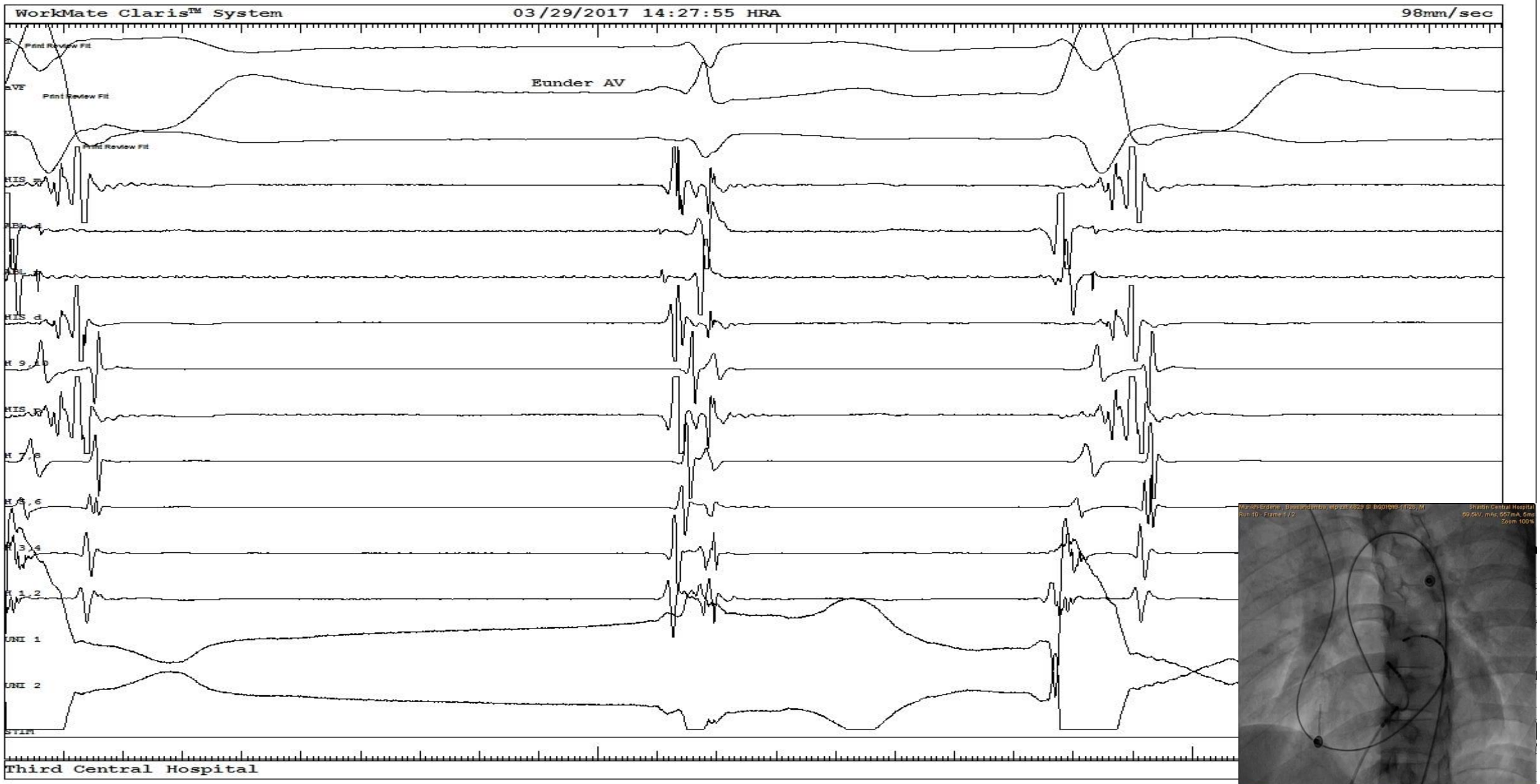

Ablation catheter on RCC

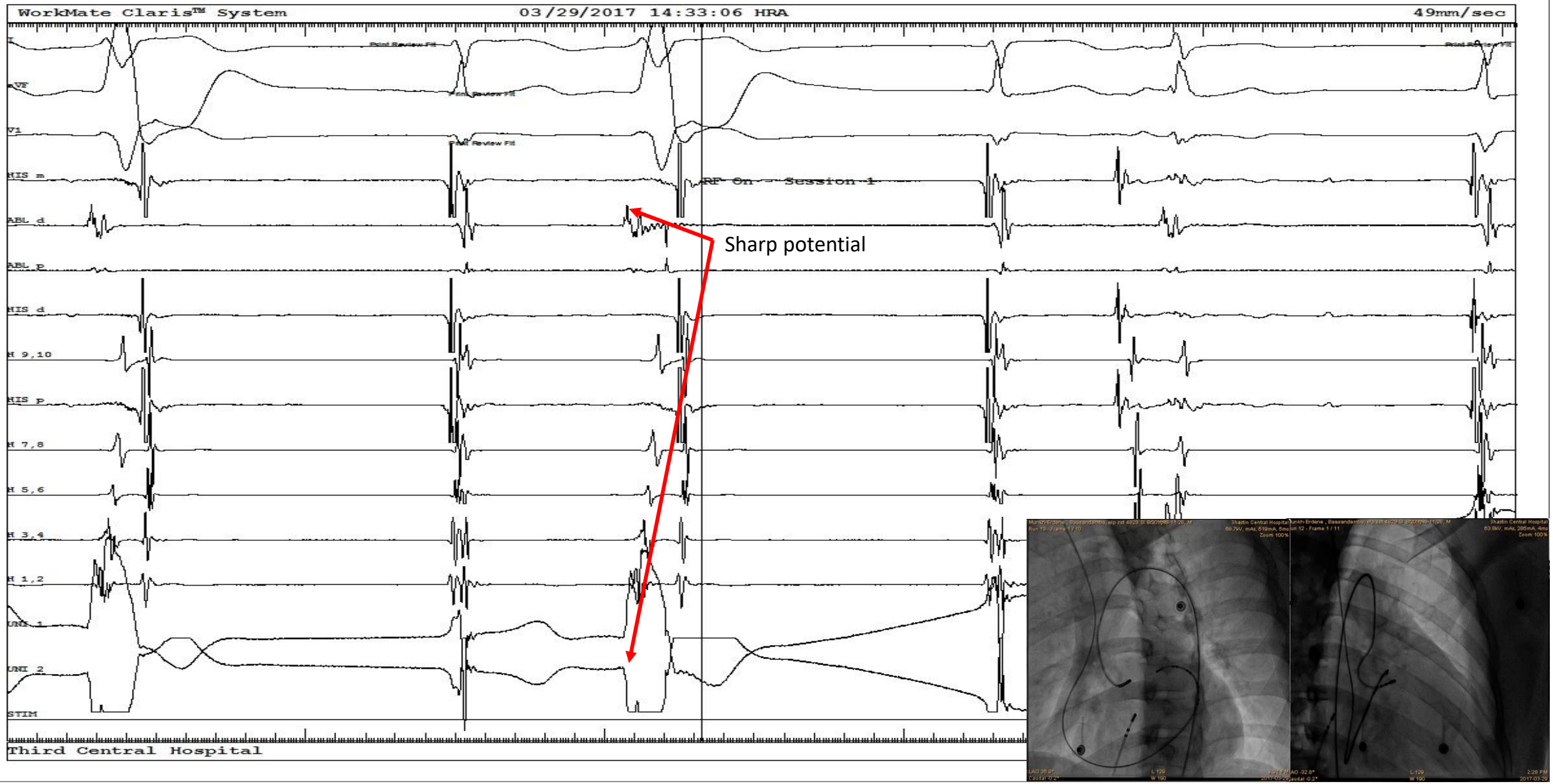

Exit site of PVC

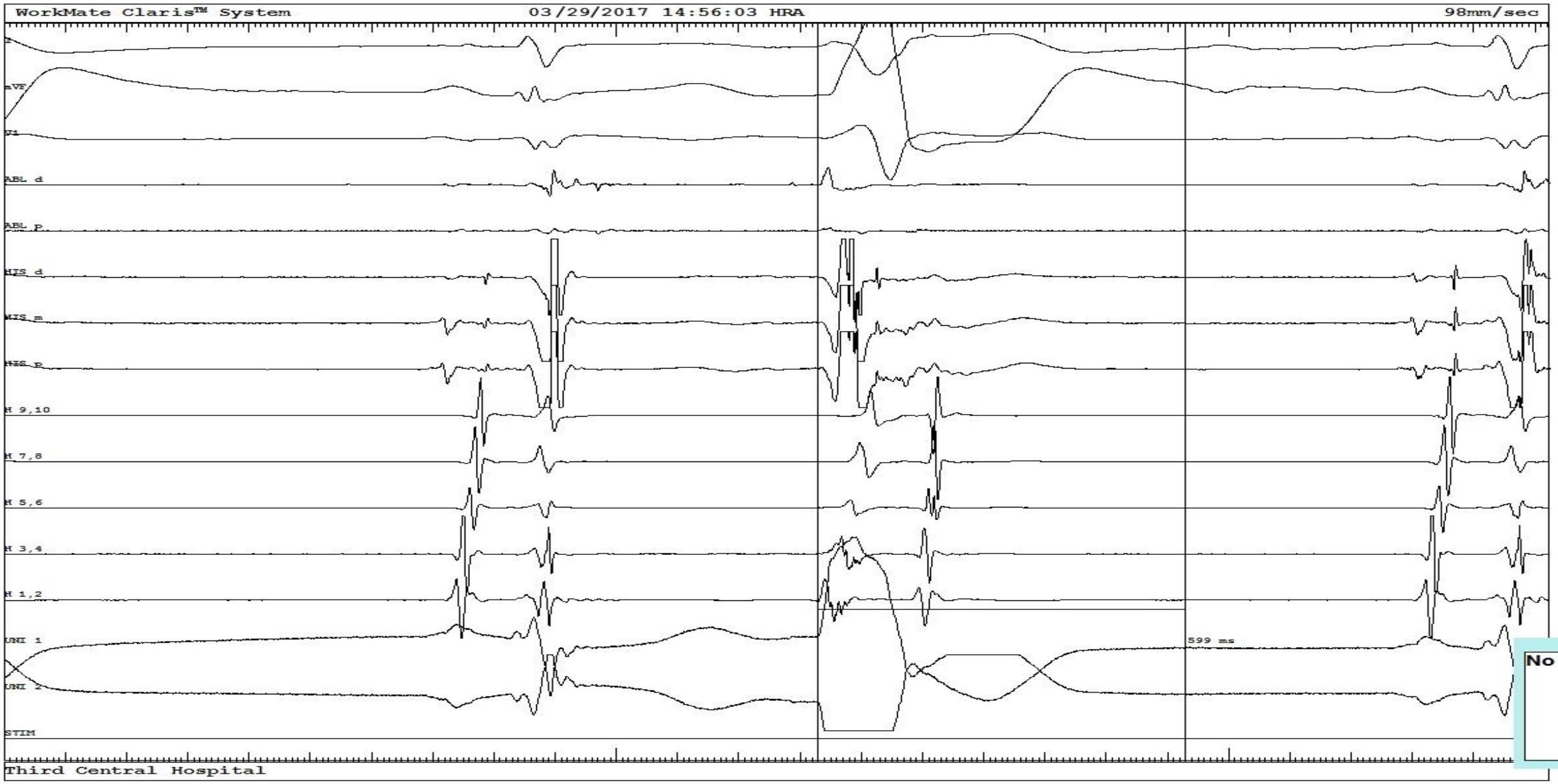

Early Potential on ablation catheter

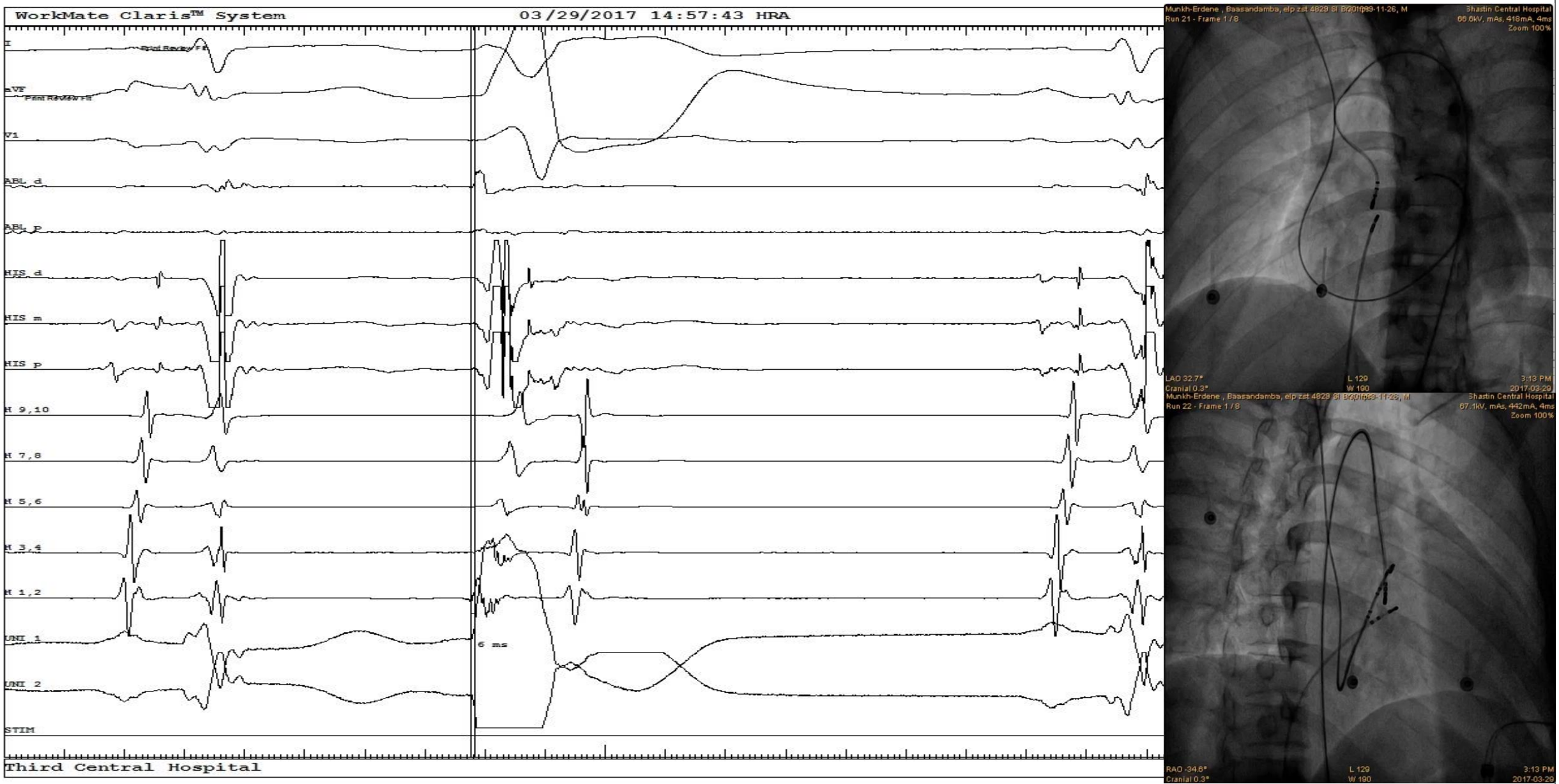

PVC location

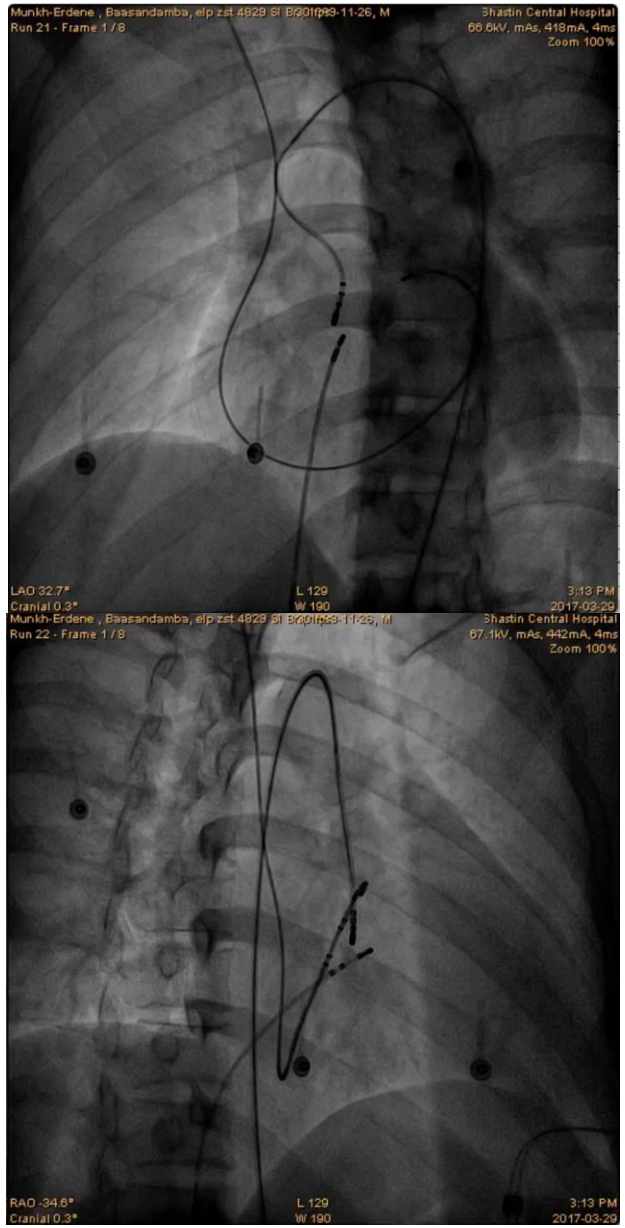

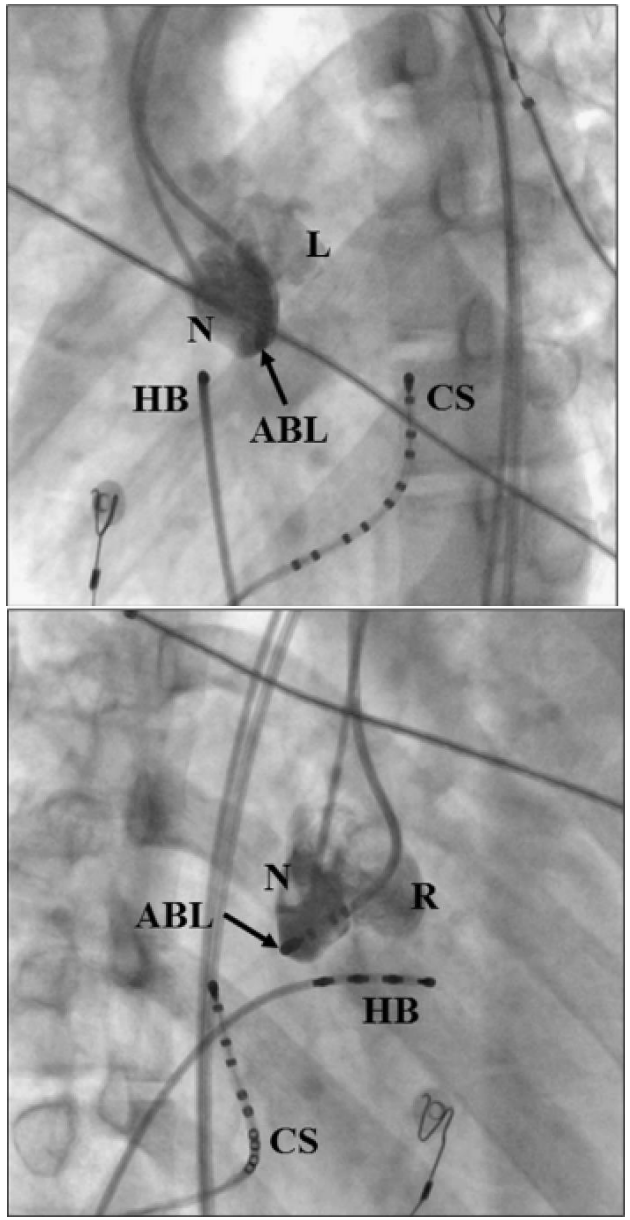

Yamada T, et al.,Heart Rhythm 2013;10:1605–1612

Anatomy of LVOT

Prevalence and clinical, electrocardiographic, and electrophysiologic characteristics of ventricular arrhythmias originating from the noncoronary sinus of Valsalva

Takumi Yamada, MD,* Yung R. Lau, MD,† Silvio H. Litovsky, MD,‡ H. Thomas McElderry, MD, FHRS,* Harish Doppalapudi, MD, FHRS,* Jose Osorio, MD,* Vance J. Plumb, MD,* G. Neal Kay, MD*

*From the *Division of Cardiovascular Disease, University of Alabama at Birmingham, Birmingham, Alabama, †Department of Pediatric Cardiology, University of Alabama at Birmingham, Birmingham, Alabama and ‡Department of Pathology, University of Alabama at Birmingham, Birmingham, Alabama.*

BACKGROUND Idiopathic ventricular arrhythmias (VAs) can be rarely ablated from the noncoronary cusp (NCC) of the aorta.

OBJECTIVE The purpose of this study was to investigate the prevalence and the clinical, electrocardiographic, and electrophysiologic characteristics of idiopathic NCC VAs.

METHODS We studied 90 consecutive patients who underwent successful catheter ablation of idiopathic aortic root VAs (left coronary cusp [LCC] 33, right coronary cusp [RCC] 32, junction between LCC and RCC 19, NCC = 6).

RESULTS NCC VAs occurred in significantly younger patients (all <40 years old) and exhibited a shorter QRS duration (all but one <150 ms), smaller R-wave amplitude ratio in leads II and III (III/II), earlier ventricular activation in the His bundle (HB) region (all but one preceded QRS onset by >25 ms), and larger atrial to ventricular electrogram amplitude ratio (A/V) at the successful ablation site (all but one >1) than the other VAs. QRS morphology of the NCC VAs was similar to that of RCC VAs, but NCC VAs always exhibited a left bundle branch block and left superior (n = 1) or inferior axis (n = 5). All NCC VAs exhibited ventricular tachycardias, although premature ventricular contractions were dominant in the other VAs.

CONCLUSION NCC VAs were very rare (7%) and occurred in significantly younger patients than those among the other aortic root VAs. In a limited set of six patients, the ECG and electrophysiologic characteristics of NCC VAs were similar to those of RCC VAs but were characterized by narrower QRS duration, smaller III/II ratio, earlier ventricular activation in the HB region, and A/V ratio >1 at the successful ablation site.

KEYWORDS Ventricular arrhythmia; Noncoronary cusp; Prevalence; Characteristics; Radiofrequency catheter ablation

ABBREVIATIONS **ASC** = aortic sinus cusp; **HB** = His bundle; **LCC** = left coronary cusp; **LV** = left ventricle; **NCC** = noncoronary cusp; **PVC** = premature ventricular contraction; **RCC** = right coronary cusp; **RF** = radiofrequency; **RV** = right ventricle; **RVOT** = right ventricular outflow tract; **VA** = ventricular arrhythmia; **VT** = ventricular tachycardia

(Heart Rhythm 2013;10:1605–1612) © 2013 Heart Rhythm Society. All rights reserved.

Yamada T, et al. Heart Rhythm 2013;10:1605–1612

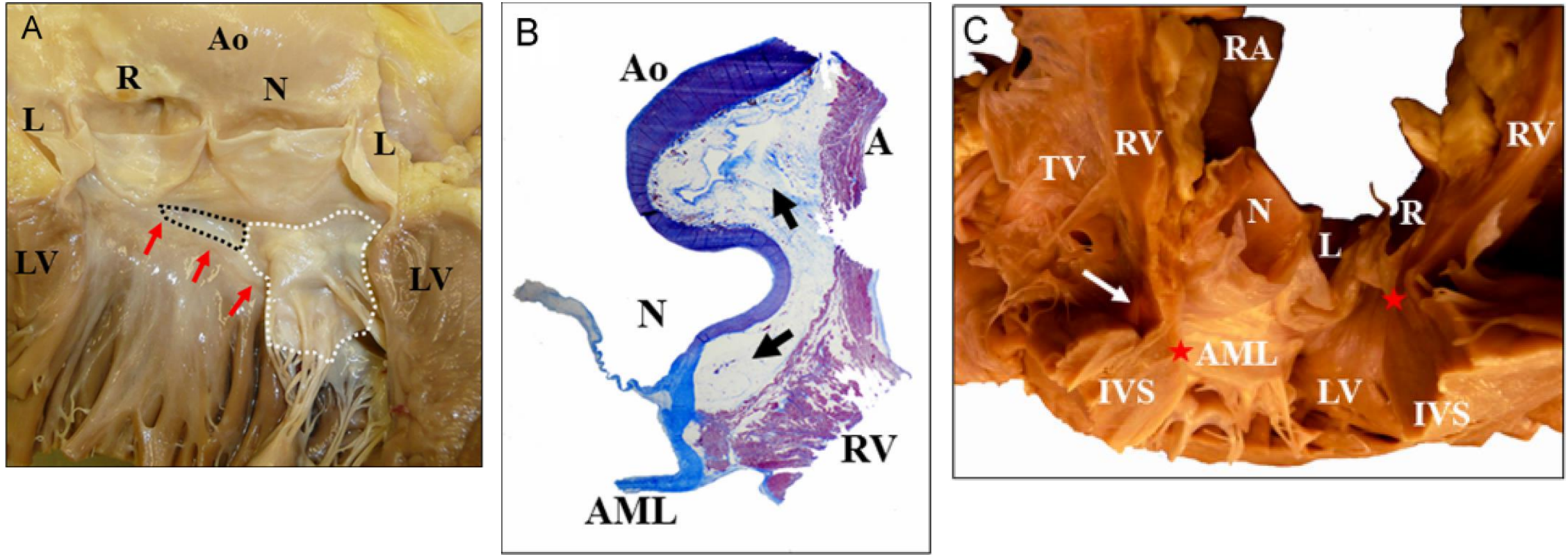

Yamada T, et al. Heart Rhythm 2013;10:1605–1612

Take home message

- Carefully evaluate surface ECG, there must be all clues
- Few drugs for PVC control (1st option for LVOT/PVC)
- Ablation is difficult when PVC are not very frequent during EP study